

SURGERY

UDC 616.757.7-007.681-089:004.932

Photo documentation in Dupuytren's disease surgery*A. V. Zhigalo*¹, *A. V. Ryapolov*², *V. V. Morozov*^{1,3},
*V. V. Pochtenko*¹, *V. I. Malyshev*²¹ LLC International Medical Center "SOGAZ",
8, Malaya Konushennaya ul., St. Petersburg, 191186, Russian Federation² S. M. Kirov Military Medical Academy,
6, ul. Akademika Lebedeva, St. Petersburg, 194044, Russian Federation³ FSBI "Federal scientific center of rehabilitation
of the disabled named after G. A. Albrecht"
Ministry of labour of the Russian Federation,
50, Bestuzhevskaya ul., St. Petersburg, 195067, Russian Federation

For citation: Zhigalo A. V., Ryapolov A. V., Morozov V. V., Pochtenko V. V., Malyshev V. I. Photo documentation in Dupuytren's disease surgery. *Vestnik of Saint Petersburg University. Medicine*, 2019, vol. 14, issue 3, pp. 204–215. <https://doi.org/10.21638/spbu11.2019.303>

Due to the rapid development of technology in the 21st century, the imaging and image processing became available to everyone. High-quality photos can be made by a regular smartphone. The high quality of current photos allows such images to be used in medicine for reporting documentation, remote consultation, as well as evaluation of treatment results. The main objective of this work is to describe rules and introduce standards of digital photography of Dupuytren's disease surgery for obtaining high-quality photo documents. The materials for our study were represented by more than 60,000 digital photos for the period from 2003 to 2017. After studying, organizing, and processing of images, the optimal conditions, standard projections, and principles of photographing hands of Dupuytren's disease patients were revealed to obtain the most reliable data. The stage of the disease, the number of palmar aponeurosis cords involved in the pathological process, the presence of changes on the skin (postoperative scars, skin retractions, nodes of the palmar aponeurosis), and finger flexion function can be assessed from photo documents. The data obtained from photos were checked against those obtained from patient examination. The described methods and standards will help in creating a high-quality personal photo and video archive, which is necessary for every practicing surgeon for systematization of observations, evaluation of long-term results, and demonstration of obtained results to colleagues as evidence. The authors are sure that in the nearest future we will become witnesses and participants of creation of a unified global database of clinical observations. The development of this resource

will allow the efforts of surgeons from all over the world to be joined in the fight against a common enemy — Dupuytren's disease.

Keywords: Dupuytren's disease, documentary photography, palmar aponeurosis.

Introduction

For a long time, since the first photographic images appeared in the early 19th century in France, the use of photography in medicine was limited because of the process of making a photo was expensive and technically complex. Due to the rapid development of technology in the 21st century, the creation and processing of images became available to everyone. Photos have acquired color, and it is now possible to take a good photo using a regular smartphone. The high quality of modern images and their accessibility allow such images to be used in medicine to create reporting documents, conduct remote consultations, and also to evaluate the results of patient treatment.

In the available literature, we did not find unified requirements and standards for the implementation of digital photos of hands of the patients with Dupuytren's disease, which prompted us to devote a scientific article this. The main task of the work was to describe the rules and introduce standards for the performance of digital photos in Dupuytren's disease surgery for creating high-quality photo documents. After all, even the most detailed description of the local status cannot be compared in reliability with a quality photo of the hand.

The material

The material for our study was more than 60 thousand digital photographs performed in the period from 2003 to 2017. After studying, organizing and processing received images, optimal conditions, standard projections and principles of photographing hands of patients with Dupuytren's disease were revealed to obtain the most reliable data. The analysis of the correspondence of the data obtained from the photo and in-patient examination was carried out.

Photographing conditions

As a result of the analysis of the images, we determined the main factors (Fig. 1. Hereinafter all pictures / photos / schemes are made by us — A. V. Zhigalo, A. V. Ryapolov, V. V. Morozov, V. V. Pochtenko, V. I. Malyshev) that affect the quality of photo and formulated conditions for photographing hands of the patients with Dupuytren's disease.

External background (background). It is mandatory to use a monochrome background, when photographing the hands of patients. It can be dark or relatively light. In the presence of sufficient contrast (in color) and illumination of the background and the object, the contours of the object can be estimated with acceptable accuracy even under different photography conditions. Most importantly there should be no gleams of light in the external background, and the background itself should be sufficiently monochrome (Fig. 2).

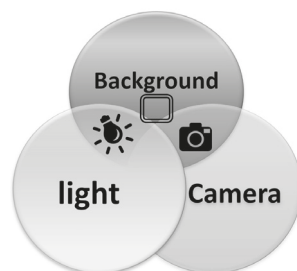


Fig. 1. Factors affecting the quality of photo

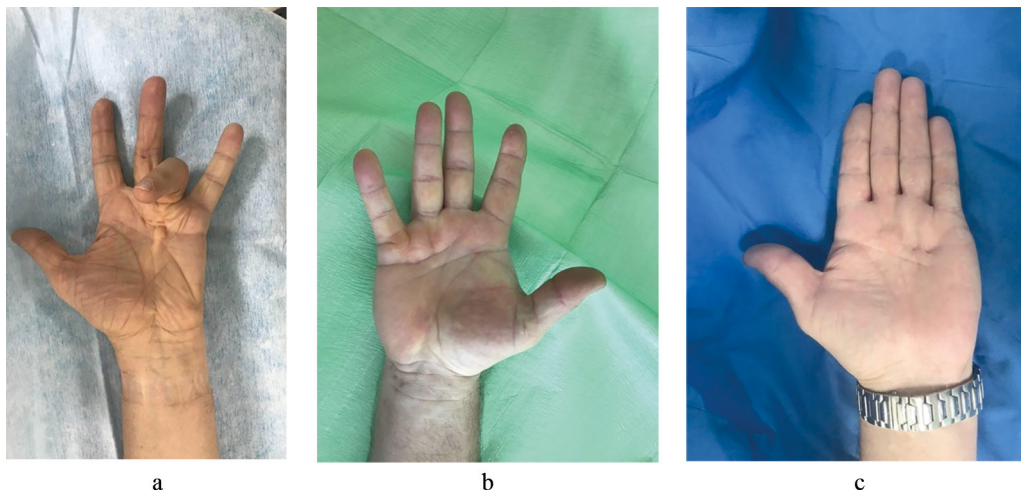


Fig. 2. Samples of the external background (sterile disposable surgical sheets of light, green and blue colors are used as background): a) light background; b) green background; c) blue background

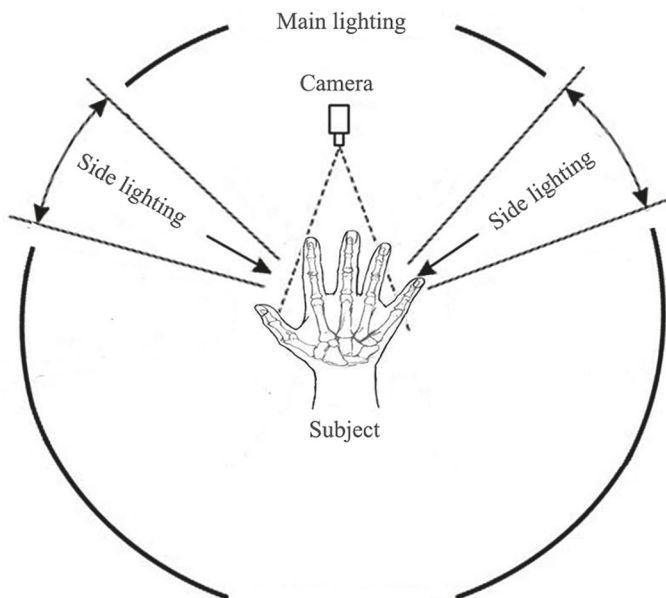


Fig. 3. The scheme of lighting the hand when taking photographs

Illumination of the object (light). One of the main factors that affects the quality of photo is the proper lighting of the patient's hand. We recommend using a constant light directed at an angle of 20–30 degrees from the side and front of the hand (Fig. 3), so it allows you to better evaluate the relief of the skin of the hand (it is desirable to use several light sources). However, if the natural light is bright enough and directed from above, then the relief of the skin folds in the photos may “disappear” (as well as when using a flash).

Device for digital photography (camera). “The more expensive and more professional the camera, the better the quality of photography” is one of the misconceptions

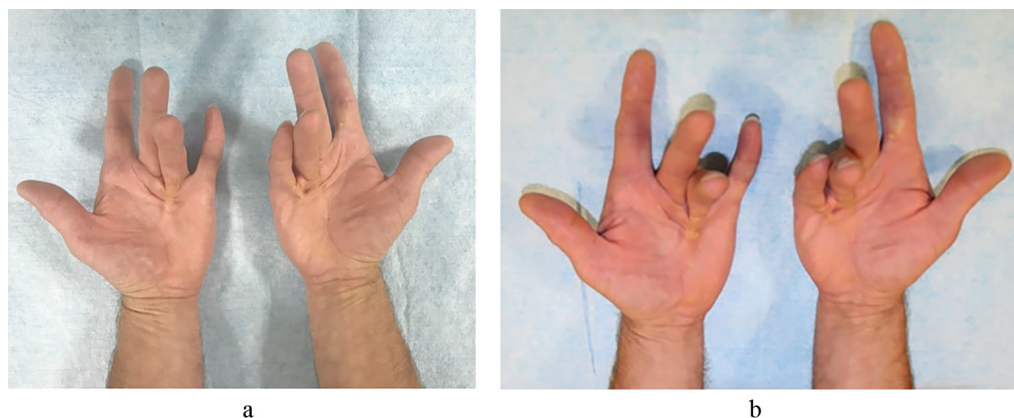


Fig. 4. An example of photos of the hands of the same patient with Dupuytren's disease made by a nurse under identical shooting conditions with: a) an integrated iPhone 7 camera (clear contours and relief of skin folds); b) expensive digital professional camera CANON (the contour is blurred, the skin relief is smoothed)

faced by a practicing surgeon who decided to start keeping a digital archive of clinical observations. This is not true, because most doctors do not have special skills to work with a professional camera; in addition, during work, you have to contact the junior medical staff for help in making a photo. That's why it's impossible to set shooting modes correctly and it's easier to make a high-quality photo on a regular smartphone or an inexpensive camera with good automatic settings (Fig. 4).

Recommendations (personal experience)

Usually we took photos of hands in the dressing room or in the operating room, photographing each hand separately. The patient's position was either lying on the operating table (the hand is on a special stand), or sitting on a chair with a hand on the dressing cart (Fig. 5).

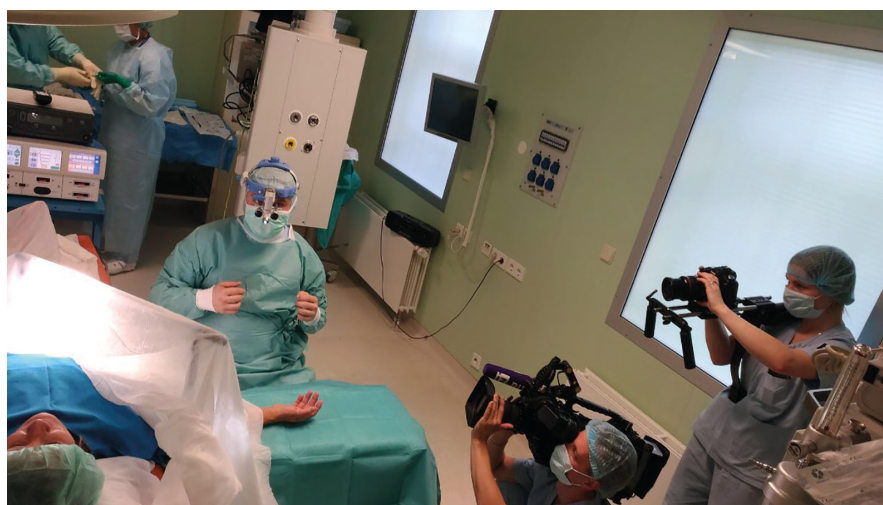

Fig. 5. Appearance of the patient in the operating room before taking a photo

Background — used a monochrome tissue, usually it was a sheet to limit the operation field: light blue, blue or green.

Light — a source of constant light, usually two operating lamps at an angle of 20–30 degrees from the side in front and behind the patient's hand, in order to avoid the appearance of additional shadows in the palm of hand.

Camera — in our practice, we tested a variety of models of digital cameras, but finally chose the Sony Alpha NEX-5N. Even the person who took this camera for the first time can take a very high quality photo in poor lighting conditions, even with a standard lens. From smartphones, Apple iPhone 6 and later models of this manufacturer proved very well.

Standard projections for photos of hands

Images for the creation of photographic documentation of Dupuytren's disease should allow one to evaluate:

- stage of disease;
- the number of palmar aponeurosis cords involved in the pathological process;
- the presence of changes on the skin (postoperative scars, skin retractions, cords and nodes of the palmar aponeurosis);
- function of flexion of fingers.

It is almost impossible to accurately document all the parameters in one photo, so different angles (projections) are required for photographing hands of patients with Dupuytren's disease.

Long-term personal experience in the implementation of digital photos and analysis of available illustrations of other authors allowed to conclude that the optimal for photo documentation for Dupuytren's contracture are three projections: frontal, three-quarters and lateral. They give the maximum reliability of the image and allow to evaluate all listed criteria.

A frontal projection allows to estimate the presence of changes on the skin (postoperative scars, skin retractions, cords and nodes of the palmar aponeurosis). Practically imperceptible postoperative scars or nodes of the palmar aponeurosis (if any) can be conditionally depicted by a marker.

It is performed from the palm of the hand, with the capture of the hand from the wrist joint to the tips of all fingers, while the hand lies on the table and is maximally extended. The background is monophonic, the illumination is constant, without flash.

It is impossible to reliably estimate in such a projection the stage of Dupuytren's disease and the number of cords of palmar aponeurosis involved in the pathological process (Fig. 6).

The projection at three-quarters allows one to estimate the number of cords of palmar aponeurosis involved in the pathological process. Practically imperceptible cords in the palmar aponeurosis (if any) can be indicated with a marker.

It is performed from the little finger at an angle of 45 degrees to the palm of hand, with the capture of the hand from the wrist joint to the tips of all fingers, while the hand lies on the table and is maximally extended. The background is monophonic, the illumination is constant, without flash.

It is impossible to reliably estimate in such a projection the stage of Dupuytren's disease and changes in the skin (Fig. 7).

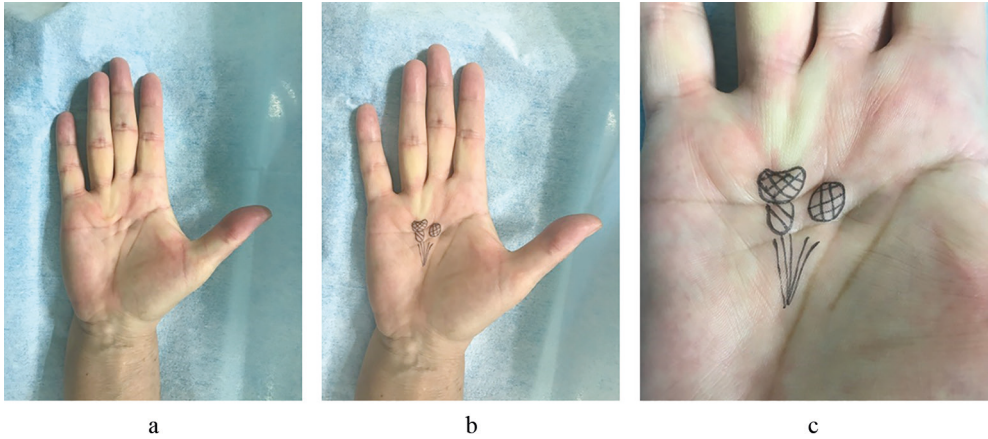


Fig. 6. Frontal projection: a) picture of the patient's hand with Dupuytren's contracture without notation; b) the marker indicates palpable changes in the palmar aponeurosis (lines — palpable cords, circles — nodes), postoperative scars are noted; c) magnification (x3.5) of the zone of changes in the palmar aponeurosis

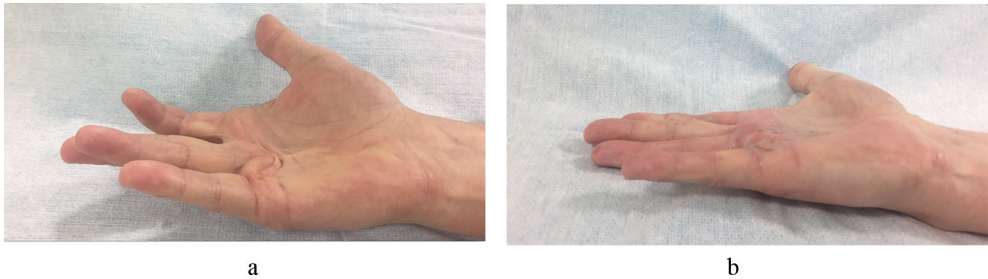


Fig. 7. Three-quarter projection: a) a picture of a patient's hand with Dupuytren's disease before surgery, 2,3,4 and 5 cords of the palmar aponeurosis are involved in the pathological process; b) picture of the hand immediately after a minimally invasive operation (needle aponeurotomy)

The lateral projection allows to estimate the stage of Dupuytren's contracture from the maximally affected cord of palmar aponeurosis.

It is performed strictly from the little finger, with the capture of the hand from the wrist joint to the tips of all fingers, while the hand lies on the table and is maximally extended. The background is monophonic, the illumination is constant, without flash.

It is difficult to reliably estimate in such a projection the number of cords of palmar aponeurosis involved in the pathological process and changes in the skin (Fig. 8).

Evaluation of the function of flexion of fingers. The evaluation of hand's function of flexion of fingers of the with Dupuytren's disease in most reliable way is possible in projections of three quarters or in a frontal, with the capture of the hand from the wrist joint to the tips of all fingers, while the hand lies on the table and is maximally extended. The background is monochrome, the illumination is constant, without flash.

A photo with an evaluation of the flexion function was performed only with its various violations, for example, in the contracture of the distal interphalangeal joint in the form of a "buttonhole" (Fig. 9).

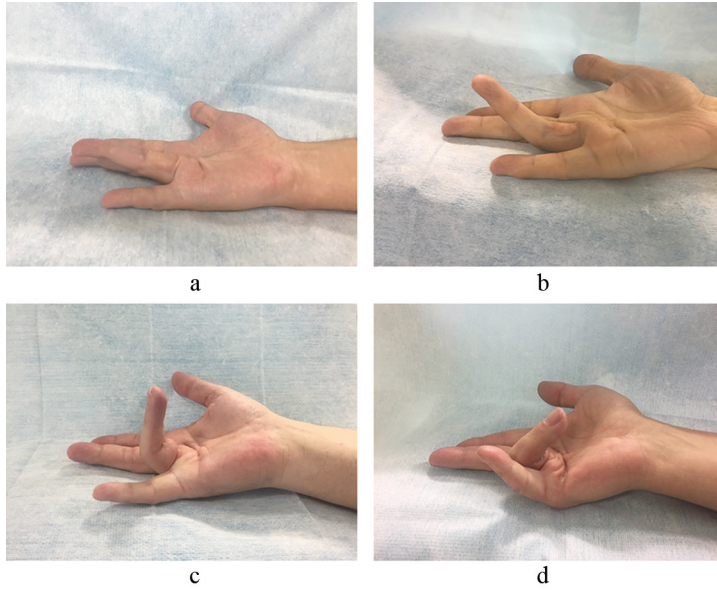


Fig. 8. Lateral projection: a) photo of the patient's hand with first stage Dupuytren's disease (4CxPxI); b) photo of the patient's hand with II stage Dupuytren's disease (4CxPxII); c) photo of the patient's hand with III stage Dupuytren's disease (4CxPDxIII); d) photo of the patient's hand with IV stage Dupuytren's disease (4CxPDxIV)

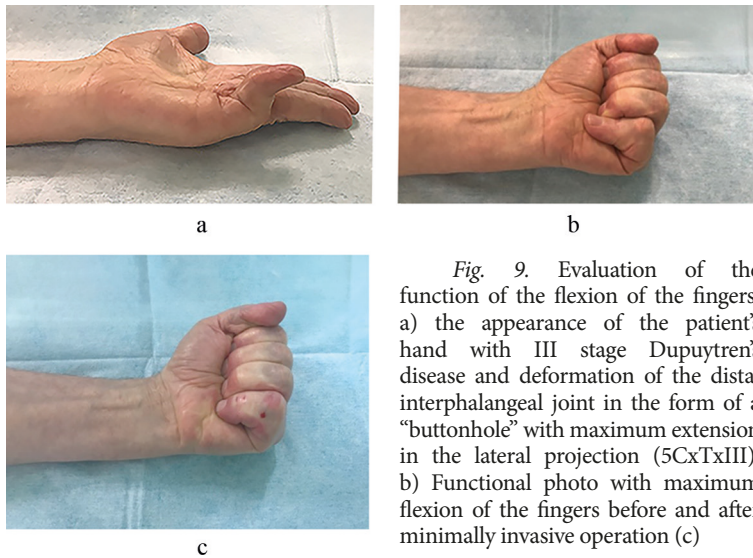


Fig. 9. Evaluation of the function of the flexion of the fingers: a) the appearance of the patient's hand with III stage Dupuytren's disease and deformation of the distal interphalangeal joint in the form of a "buttonhole" with maximum extension in the lateral projection (5CxTxIII); b) Functional photo with maximum flexion of the fingers before and after minimally invasive operation (c)

Discussion

In summary, it should be specially noted that all the listed projections are important for the creation of photo documentation. It is possible to reliably estimate the stage of contracture, the number of palmar aponeurosis involved in the pathological process, the presence of changes on the skin (postoperative scars, skin retractions, cords and nodes of the palmar aponeurosis) and the function of flexion of fingers only having photos of hands in the proposed positions.

It is mandatory to observe the same conditions for photo registration of the hand at different observation times to reliably evaluate the results of treatment of patients with Dupuytren's disease, in addition to the listed photo projections.

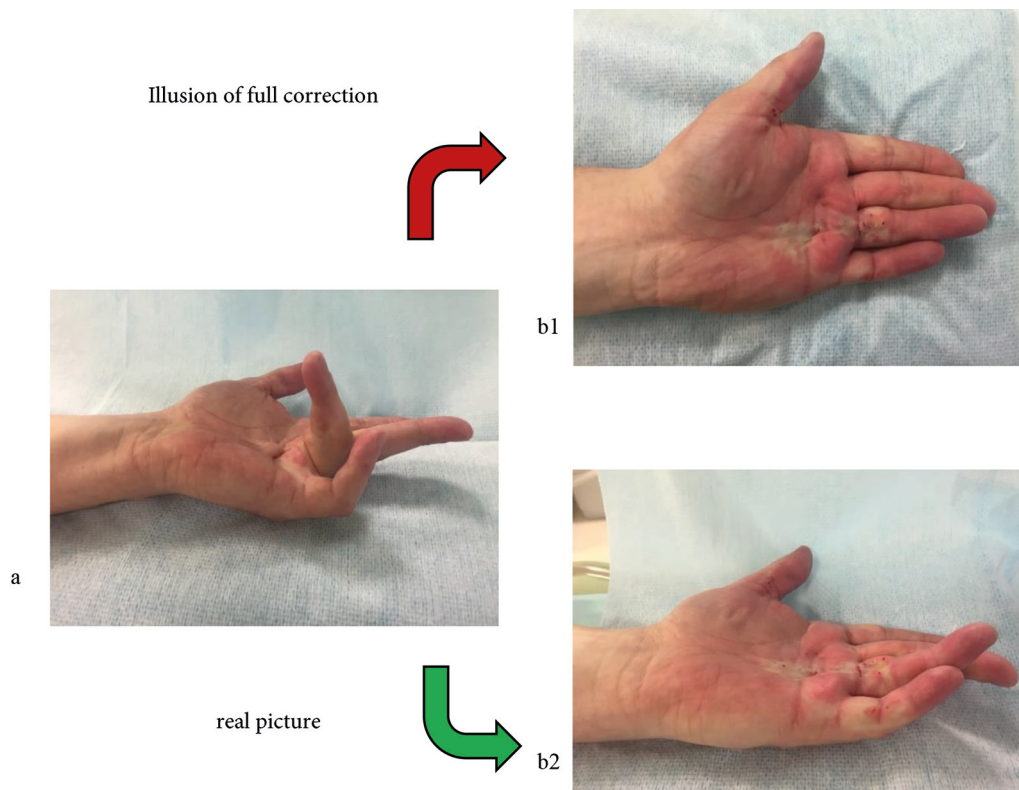


Fig. 10. An example of the use of a frontal projection to visually improve the stage of correction of the contracture of the fingers after surgery: a) the appearance of the patient's hand with III stage of Dupuytren's contracture (4CxPDxIII); b) the appearance of the hand after the operation in the frontal (b1) and lateral (b2) projections. There is a visual improvement in the degree of correction of contracture in a frontal projection, but there is not visual improvement in the lateral

Surgeons often specially neglect these rules to create a more winning image after the operation (Fig. 10). By standardizing approaches to photo documentation, such tricks will be a thing of the past.

Assessment of the stage of DD and the hardness of the nodules by photos

Assessment of the hardness of the nodules of DD before and after the treatment is extremely important, but is considered to be impossible by ordinary photos. To create a photographic documentation we developed a method by painting (Fig. 11) a special pattern on nodules of the aponeurosis appropriating to its hardness.

We defined three stages of hardness of the nodules — soft, medium hard and hard. We measured the superficial hardness of the nodules of the palmar aponeurosis using the Shor digital durometer in international hardness units from 30 to 100 in our case.

Using such devices is not always possible in clinical practice because of their high cost, therefore we suggest an alternative method of measuring hardness using references with known indexes of international hardness units. We recommend the usual stationery and household items as such standards (Fig. 12).

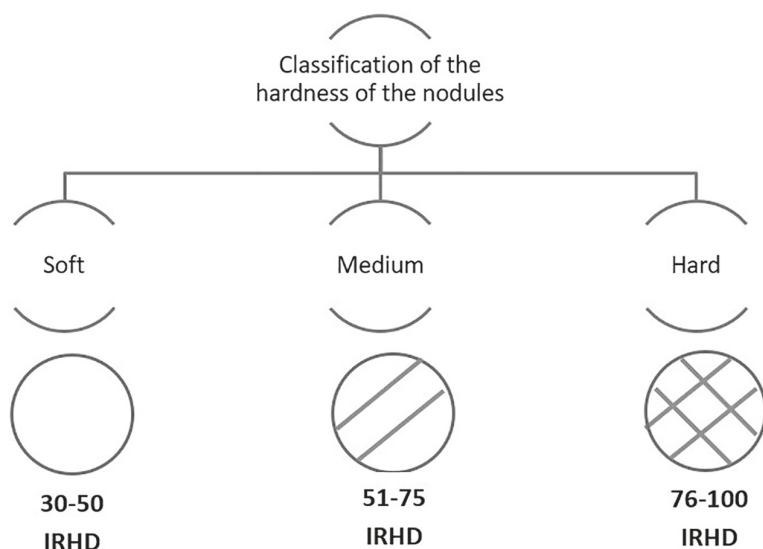


Fig. 11. Classification of the hardness of the nodules of the palmar aponeurosis, appropriate graphic symbols and indexes at the international units IRHD (international rubber hardness degree)

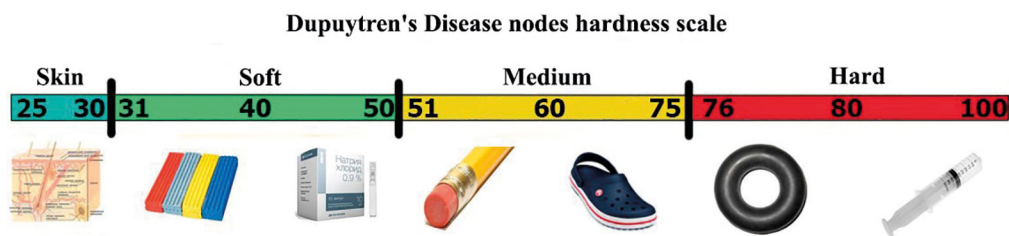


Fig. 12. Scale of accordance of different subjects with hardness indexes (IRHD units)

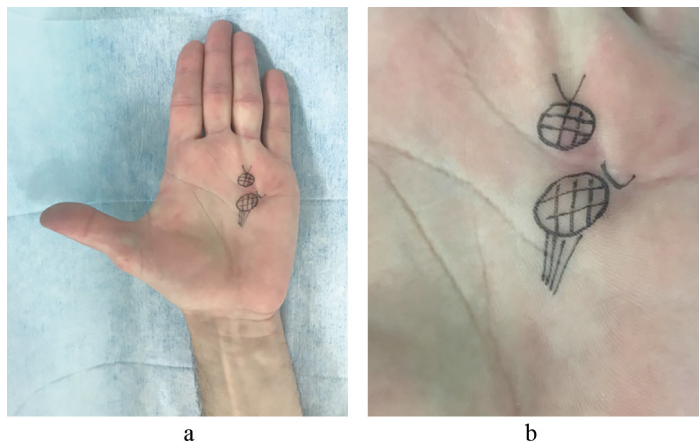


Fig. 13. The photo of the patients' hand with I (0I) stage of CD in a direct projection (4CxPx0I): a) general view; b) x3,5 enlargement. In the projection of the 4 cord palmar aponeurosis two hard nodules are depicted (shaded by the grid). Retraction of the skin is marked by 'V'

To evaluate the results of the treatment before and after the operation, we marked the palpable nodules of the palmar aponeurosis with a marker and shaded depending on its hardness (Fig. 13); the length and width were measured by the ruler in millimetres. Photos before and after the treatment were performed in a direct projection. The results were compared by measuring the density and size of the nodules.

Hands' function assessment by short videos

Video shooting conditions

We found that the optimal position for the shooting of short video clips for evaluating the function of flexion and extension of the fingers is the three quarters projection that is described above. There is no necessity to purchase a professional camera for this purpose — a usual camera or a smartphone will be sufficient. The video shooting conditions (background, light, camera) are also identical to those we recommended for the photos.

Requirements for videos and placement on YouTube

To assess the function of the hand a video shooting 2–3 cycles of movements — bending fingers into a fist and fully expanding them will be enough. It takes about 3-5 seconds of video recording. The recording of the function before and after the operation was performed under the same conditions. The videos were uploaded to the site <https://www.youtube.com/> (in Russian YouTube literally sounds like “your TV channel”), the most popular video hosting in the world allowing to store, send and demonstrate video clips. Unfortunately, it is impossible to print the recorded video on paper, but it is quite possible to point an electronic link to their location on the World Wide Web in the text under the picture. By entering this link you can play the required video.

QR-code creation

For easy playback of the videos from mobile devices, this link can be encoded as QR code. You can create any QR code yourself and absolutely free at <http://qrcoder.ru/>.

QR-code recognition

There are many special programs for mobile devices on the operating system iOS — Bakodo, Scan (line smartphones iPhone) and Barcode Scanner, QuickMark Lite QR Code Reader for the Android operating system (Samsung smartphone line, etc.) to recognize QR codes. We applied the QR Reader program on the iPhone 7, it can be downloaded for free in the App Store.

How to scan QR-code

To scan the QR-code use a smartphone or tablet with the camera and the installed QR-code scanner (applications can be downloaded for free in the App Store or on the Android Market).

- Run the QR scanner and point the camera of the device to the code.
- The program decrypts the contents of the code — the text will display on the screen or the information coded by the link will be automatically loaded.

Example of creating a video about hand function

As described above, we recorded a short video of the function of a patient's hand with Dupuytren's contracture before and immediately after surgery (Fig. 14).

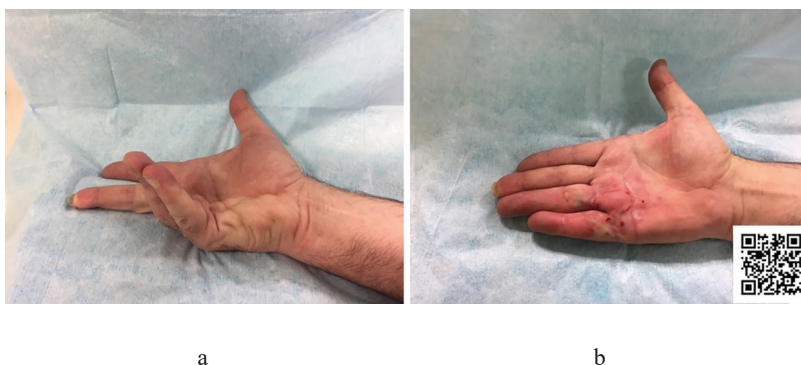


Fig.14. Appearance of the patient's hand with Dupuytren's contracture (45CxPxII): a) before and b) after needle aponeurotomy. Link to the video of the patient's hand function <https://youtu.be/Y7jOnhe-0rU> and its QR code

Video shooting conditions:

background — light blue (surgical sheet disposable);

lighting — a constant source of light (lighting in the operating room);

camera — the built-in camera of the smartphone iPhone 7.

The projection of the filming is three quarters.

Recorded videos before and after the operation were connected together using the built-in program iMovie with the addition of the date and time of shooting. The video was uploaded to the site <https://www.youtube.com/> (you can create your own channel on this site for uploading videos) from the smartphone. The link to the video was converted into a QR code on the site <http://qrcoder.ru/>.

Conclusion

The described methods and standards will help creating a high-quality personal photo and video archive, which is necessary for each practicing surgeon for standardizing observations, evaluating long-term results, and also for demonstrating their achievements to colleagues as evidence. The authors are sure that in the near future we will become witnesses and participants in the creation of a unified world database of clinical observations of patients. The appearance of such a resource will allow to unite the efforts of surgeons from all over the world in the fight against a common enemy — Dupuytren's disease.

References

1. Belousov A. Ye. *Sketches of plastic surgery. Vol. 3: Surgeons and patients*. Moscow, Prakticheskaya medicina Publ., 2015. 136 p. (In Russian)
2. Belousov A. Ye. Photo-evidence in plastic surgery. *Plasticheskaja khirurgija i kosmetologija*, 2012, no. 1, pp. 19–29. (In Russian)
3. Gubochkin N. G., Shapovalov V. M. *Selected issues of hand surgery*. St. Petersburg, Professional Publ., 2008. 288 p. (In Russian)
4. Zhigalo A. V., Pochtenko V. V., Morozov V. V., Stadnichenko S. Yu. Minimally invasive needle aponeurotomy in the treatment of patients with Dupuytren's contracture. *Voprosy rekonstruktivnoi i plasticheskoi hirurgii*, 2017, vol. 20, no. 3, pp. 33–44. (In Russian)
5. Zhigalo A. V. *Features of surgical treatment tactics for patients with severe degrees of Dupuytren's contracture*. Dis. Cand. Med. Sci. St. Petersburg, 2010. 111 p. (In Russian)
6. Eaton C. Percutaneous fasciotomy for Dupuytren's contracture. *J. Hand. Surg. Am.*, 2011, May, 36 (5), pp. 910–915.
7. Golgwyn R. M. *The patient and the plastic surgeon*. 2nd ed. Boston, Toronto, London, Little, Brown and Co., 1991.
8. Werker P., Dias J., Eaton C., Reichert B., Wach W. (Eds). *Dupuytren Disease and Related Diseases. The Cutting Edge*. Springer International Publishing, Cham, 2017. 448 p.

Received: August 14, 2019
Accepted: November 17, 2019

Authors' information:

Andrei V. Zhigalo — MD, PhD; handcenter@mail.ru
Victor V. Morozov — MD
Vladimir V. Pochtenko — MD